

Blood cytology of the common jollytail (*Galaxias maculatus*) (Jenyns, 1842) (*Osmeriformes: Galaxiidae*) at postlarval and adult stages

Estudio de la citología sanguínea del puye (*Galaxias maculatus*) (Jenyns, 1842) (*Osmeriformes: Galaxiidae*) en estado postlarval y adulto

I Valdebenito^{a, b*}, K Busse^c, N Jaramillo^a, A Hernández^{a, b}

^a Escuela de Acuicultura, Facultad de Recursos Naturales, Universidad Católica de Temuco, Chile.

^b Centro de Genómica Nutricional Agroacuícola, Temuco, Chile.

^c Museum Alexander Koenig, Bonn, Germany.

RESUMEN

El puye (*Galaxias maculatus*) es un pequeño pez nativo de gran interés para la diversificación de la acuicultura chilena, debido al alto valor comercial de su estado postlarval cristalino. La presente investigación entrega los primeros antecedentes respecto de la citología sanguínea de postlarvas y adultos de esta especie, determinada mediante microscopía óptica utilizando frotis sanguíneos preparados con May Grünwald-Giemsa. Los resultados muestran que en la sangre circulante de *G. maculatus* en estado de postlarva no se observan eritrocitos maduros y la sangre es de aspecto transparente. Sin embargo, en adultos se pudo observar la línea eritrocitaria completa y en leucocitos no se observó la presencia de células de grano grueso como son los basófilos y eosinófilos. La morfología de las células encontradas en ambos estados del desarrollo del puye mantienen las características propias entregadas en la literatura para peces teleósteos.

Key words: fish haematology, blood cells, *Galaxias maculatus*, whitebait.

Palabras clave: hematología de peces, células sanguíneas, *Galaxias maculatus*, puye.

INTRODUCTION

Common Jollytail or “Puye” (*Galaxias maculatus*), is a small native fish that inhabits fresh and estuarine waters in Southern Chile. This species is very widespread in the Southern Hemisphere and occurs in a variety of habitats including freshwater (still or slow-flowing waters, river, lakes) and coastal streams in Australia, New Zealand, South Africa, Patagonian South America and the Malvinas Islands. Diadromic populations initiate the free life stage in brackish environments and after 4-6 months they return to freshwater as larvae with a transparent aspect and eel-like shape, and for this reason are commonly called “cristalinos” in Chile. After returning to freshwater they go through a metamorphosis phase that transforms them in pigmented juveniles with a high condition index (K) (figure 1 A and B). During the larvae transparent state, specimens are captured intensively and commercialized as a highly valuable food. Their physical attributes allow them to be considered comparable to “elvers” (i.e. transparent baby eels) and as such are well appreciated food product in Europe, New Zealand and Mexico, reaching high retail prices (Bórquez *et al* 1996, Dantagnan *et al* 2002). Currently, Chilean natural capture fisheries for “Puye” are mainly located in Araucanía, Los Ríos

and Los Lagos regions, being more prevalent in Chiloé and Aysen. However, high extractive pressure on this fish in Chile has resulted in a significant reduction of natural populations (Barile *et al* 2003). As a result of the high market value and commercial interest for “cristalinos” this fish has been described as a potential new species for Chilean aquaculture diversification. The School of Aquaculture of the Catholic University of Temuco, Chile, has been involved in the research and development of larval rearing and feeding techniques for the culture of *G. maculatus* for over ten years (Bórquez *et al* 1996, Dantagnan *et al* 2002, Barile *et al* 2003, Dantagnan *et al* 2004, Dantagnan *et al* 2005, Dantagnan *et al* 2007). The success when introducing a new species to aquaculture relies on, among other things, the detailed knowledge of the physiology of the species. Describing the cellular characteristics of the blood can provide information useful not only for the culture of the species but also for assessing the physiological status of the fish (Pavlidis *et al* 2007). The wide geographical distribution of this species and its interesting ecological attributes, as well as the existence of diadromic behavior, have attracted the attention of many ichthyologists. There are numerous studies related to different aspects (systematic, biology, natural history, population genetics, etc) of *G. maculatus* (Campos 1970, McDowall 1970, McDowall 1971, McDowall 1981, McDowall 1984, McDowall 1988, Berra *et al* 1996, Waters and Burrige 1999, Busse and Möser 2006). However,

Accepted: 07.04.2011.

* Casilla 15-D Temuco, Chile; ivisler@uct.cl

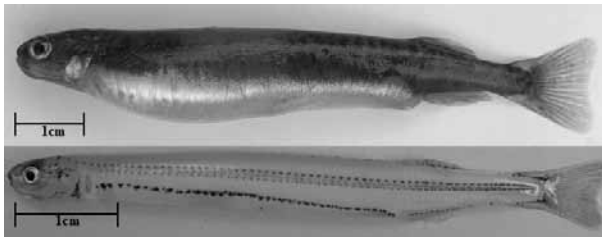


Figure 1. Adult (up) and postlarvae (down) specimens of *G. maculatus*.

Especímenes adulto (arriba) y postlarval (abajo) de *G. maculatus*.

there are still many unknown biological aspects. Besides some few works about the absent of red blood in larvae, there is scarce information regarding haematological studies in this species (Busse 1993, Busse and Campos 1996).

As mentioned previously, research concerning blood cytology studies in *G. maculatus* has been very limited. Hence, to further elucidate some of these unknown aspects a series of studies were conducted in this species under laboratory conditions. The aim of this study was to gather preliminary information about the haematological profile of *G. maculatus*.

MATERIAL AND METHODS

EXPERIMENTAL CONDITIONS

Adults sampled were reared under laboratory conditions in 0.5 m³ fiberglass tanks with a total water exchange per hour according to methods described previously (Dantagnan *et al* 1995) at the facilities of the School of Aquaculture, Catholic University of Temuco, at a stocking density of 13 kg/m³. They were hand fed commercial dry pellets for salmon (3 mm of diameter) *ad libitum* twice daily. Water source was obtained from a deep well with an average temperature of 12.5 ± 4.5° and oxygen concentration of 8.5 ± 0.5 ppm. Larvae were captured from the estuary of Toltén River in the Araucanía Region, Chile, and held in 0.5 m³ fiberglass tanks under same condition than adults. None of the fish was undergoing treatment of any kind and their health condition was considered clinically normal.

SAMPLING

Blood sampling was conducted in sixty larvae and thirty adults of *G. maculatus*, apparently healthy, with a body weight that fluctuated between 0.2 to 0.4 and 7.8 to 13.0 g respectively. Fish were anaesthetized with BZ20® (Veterquímica, Chile) and blood was taken from the caudal vein in the case of adult fish, using an insulin

syringe (1.0 cc, 29G x 1/2" needle). Blood from larvae was collected through direct heart puncture using a modified microhematocrit tube. Smears from adults and larvae were prepared immediately after blood sampling, using whole blood and stained with May Grünwald-Giemsa solution for optical microscopy following the method described by Oppenheim (1973).

MICROSCOPY

Differential cells counts were carried out in the best 10 blood smears, from either adults or larvae. The slides were examined under oil-immersion at 100X magnification using an optical microscope (Eclipse E400, Nikon). For each slide three areas were randomly chosen and 100 cells counted and recorded as either erythrocyte or leucocyte. Leucocytes were differentiated and classified into four types: lymphocytes, neutrophils, eosinophils and monocytes. Maturity state of erythrocytes and the presence and types of thrombocyte were also recorded. Cellular elements found in peripheral blood of *G. maculatus* were identified using cytological criteria based on the nomenclature proposed by Conroy (1972) for Atlantic salmon. Cells size was determined using a 10X graduated ocular (Wolfe Wetzler, Germany) with a magnification of 1000X and an accuracy of 0.09 µm.

STATISTICAL ANALYSIS

Statistical analyses of the cells size and percentages were performed using the program StatMost (Dataxiom, USA). Significant differences were determined through the application of the Student's t-test. Normality of the data was verified by the Kolmogorov-Smirnov's test. Level of significance was set at P > 0.05.

RESULTS

The results showed that circulating blood of *G. maculatus* adults is composed in a 97.64 ± 6.2% by erythrocytes, 1.34 ± 0.1% by leucocytes and 1.01 ± 0.03% of thrombocytes. Data on the differential cell counts determined in the peripheral blood from adults and larvae of *G. maculatus* are presented in table 1. This shows that mature erythrocytes were not found in larvae, although immature stages of the erythrocyte line were very abundant, such as the polychromatocytes with 68.90 ± 5.30%. However, in adults, the mature erythrocytes are the most abundant cells of the erythrocyte line with 96.34 ± 1.65% and in relation to leucocyte line the neutrophils represent 20.20% considering both, the mature and immature stages. In larvae, lymphocytes are around 69.63 ± 0.06% of the leucocytes cell types. Figure 2 presents the different types of cells identified in the blood samples from adults and larvae of *G. maculatus* expressed as cumulative percentage.

Table 1. Differential cell counts (%) determined in the peripheral blood of postlarvae and adults *G. maculatus*.Recuento diferencial (%) determinado en sangre periférica de larvas a adultos de *G. maculatus*.

ERYTHROCYTES	Postlarve	Adult
Erythroblast	22.68 ^a ± 3.02	0.05 ^b ± 0.01
Polychromatocyte	68.90 ^a ± 5.30	0.47 ^b ± 0.05
Immature erythrocytes	4.00 ^a ± 8.81	0.00 ^b ± 0.00
Mature erythrocytes	0.00 ^a ± 0.00	96.34 ^b ± 1.65
Erythrocyte in haemolysis	3.09 ^a ± 0.04	0.76 ^b ± 0.04
Ghost cell	1.1 ^a ± 0.25	2.2 ^a ± 0.24
LEUKOCYTES		
Immature neutrophil	18.42 ^a ± 0.04	17.50 ^a ± 0.05
Mature neutrophil	3.06 ^a ± 0.03	2.7 ^a ± 0.01
Lymphocyte	69.63 ^a ± 0.06	71.20 ^a ± 0.09
Monocyte	8.9 ^a ± 0.08	8.6 ^a ± 0.07
THROMBOCYTES		
Immature	2.00 ^a ± 0.37	6.00 ^a ± 0.56
Mature	98.00 ^a ± 0.60	94.00 ^a ± 0.56

Means within the same rows followed by the same superscript letters are not significantly different ($p > 0.05$). All values are means ± SD.

ERYTHROCYTE CELL LINE

Erythroblasts. The erythroblasts found among both groups of fish were round/oval-shaped, characterized by an eccentric and big rounded nucleus, with heterogeneously distributed chromatin and intense basophilic cytoplasm (figure 2A and a). Quantitative parameters in measured erythroblasts were not significantly different ($P > 0.05$) between both groups of fish (table 2).

Polychromatocytes. These cells presented a round shape with blue-grey cytoplasm and a central nucleus characterized by compact and basophilic chromatin. In larvae, cellular aggregates were observed and they were characterized by red nucleus with heterogeneous aspect (figure 2b). Polychromatocytes measured between both groups of fish did not present significant differences ($P > 0.05$) (table 2).

Mature erythrocytes. They present an elliptical form in the same way that the nucleus, which is in the center of the cell, surrounded by a slightly eosinophilic cytoplasm with homogenous aspect (figure 2C). Measures found in these cells are expressed in table 2.

Erythrocyte haemolysis. Cells that were in initial haemolysis were characterized by the increment in the nuclear size as result of kariolysis (figure 2D and d). Erythrocytes in advanced haemolysis presented a

Table 2. Linear length (µm) of cells found in the peripheral blood of *G. maculatus*.Longitud lineal (µm) de células de sangre periférica de larvas y adultos de *G. maculatus*.

POSTLARVAE	Cell		Nucleus		n
	Major axis	Minor axis	Major axis	Minor axis	
Polychromatocyte	8.09 ^a ± 1.62	– –	4.99 ^a ± 1.07	– –	50
Erythroblast	7.61 ^a ± 1.00	– –	6.09 ^a ± 0.94	– –	50
Lymphocyte	5.8 ^a ± 0.11	– –	– –	– –	50
Monocyte	10.3 ^a ± 2.17	– –	6.76 ^a ± 2.03	– –	50
Mature neutrophil	8.22 ^a ± 0.67	– –	6.44 ^a ± 1.22	– –	3
Immature neutrophil	8.77 ^a ± 1.56	– –	5.67 ^a ± 1.20	– –	50
Mature Thrombocytes	8.22 ^a ± 0.67	– –	6.44 ^a ± 1.22	– –	50
Immature Thrombocytes	6.91 ^a ± 1.58	2.35 ± 0.93	6.22 ^a ± 1.59	1.74 ± 0.42	20
ADULT					
Mature erythrocytes	9.47 ^a ± 1.08	6.88 ± 1.01	4.00 ^a ± 0.68	2.88 ± 0.58	100
Polychromatocyte	6.22 ^a ± 1.17	– –	3.41 ^a ± 1.02	– –	20
Erythroblast	6.99 ^a ± 1.06	– –	5.48 ^a ± 1.10	– –	50
Lymphocyte	3.41 ± 0.84	– –	– –	– –	50
Monocyte	10.59 ^a ± 2.34	– –	5.68 ^a ± 1.61	– –	50
Mature neutrophil	8.46 ^a ± 0.51	– –	6.35 ^a ± 1.08	– –	4
Immature neutrophil	8.37 ^a ± 1.89	– –	4.47 ^a ± 1.97	– –	50
Mature Thrombocytes	8.46 ^a ± 0.51	– –	6.35 ^a ± 1.08	– –	50
Immature Thrombocytes	7.83 ^a ± 2.35	2.53 ± 0.62	4.99 ^a ± 0.73	1.42 ± 0.73	20

Means within the same column followed by the same superscript letters are not significantly different ($P > 0.05$). All values are means ± SD.

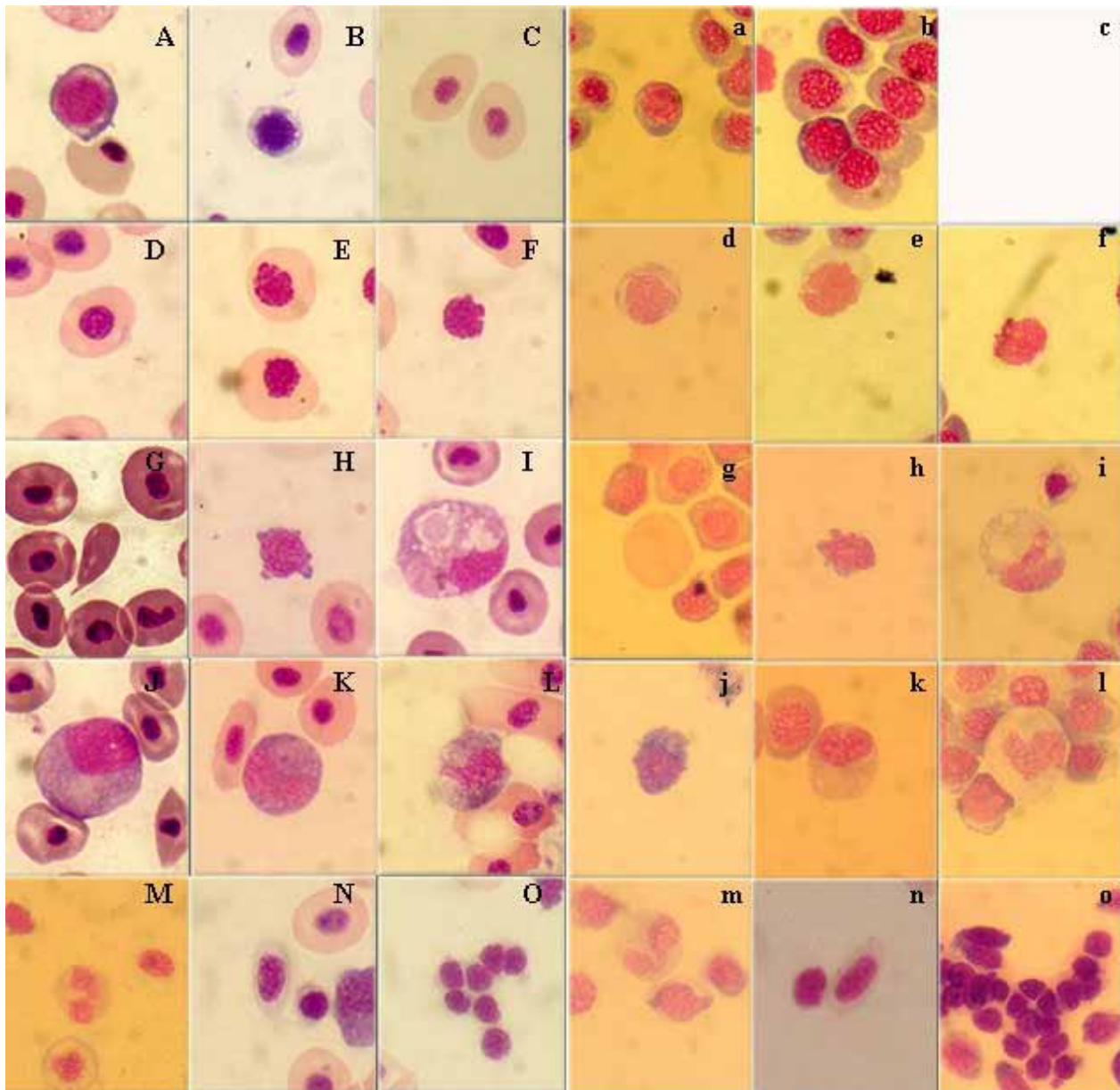


Figure 2. Microphotography of swabs taken from circulating blood of adult and postlarvae of puye (*G. maculatus*) stained with May Grönwald-Giemsa. 1000x. ADULT: A) Erythroblast. B) Polychromatocyte. C) Mature erythrocytes. D) Erythrocyte in early haemolysis. E) Erythrocyte in late haemolysis. F) Erythrocyte in late haemolysis. G) Erythroplastid. H) Lymphocyte. I) Monocyte. J) Myelocyte. K) Metamyelocyte. L) Band Neutrophil. M) Mature Neutrophil. N) Immature Thrombocytes. O) Immature Thrombocytes. LARVAE: a) Erythroblast. b) Polychromatocyte. d) Polychromatocyte in early haemolysis. e) Polychromatocyte in late haemolysis. f) Ghost cell. g) Erythroplastid. h) Lymphocyte. i) Monocyte. j) Myelocyte. k) Metamyelocyte. l) Band Neutrophil. m) Mature neutrophil. n) Immature Thrombocytes. o) Immature Thrombocytes. Each bar in all figures represents 2µm.

Microfotografía de frotis sanguíneo tomada desde sangre periférica de larvas y adultos de puye (*G. maculatus*) teñidas con May Grönwald-Giemsa. 1000x. ADULTO: A) Eritroblasto. B) Policromatocito. C) Eritrocitos maduros. D) Eritrocito en hemólisis temprana. E) Eritrocito en hemólisis tardía. F) Eritrocito en hemólisis tardía. G) Eritroplástido. H) Linfocito. I) Monocito. J) Mielocito. K) Metamielocito. L) Neutrófilo en banda. M) Neutrófilo maduro. N) Trombocitos inmaduros. O) Trombocitos inmaduros. LARVAE: a) Eritroblasto. b) Policromatocito. d) Policromatocito en hemólisis temprana. e) Policromatocito en hemólisis tardía. f) Célula fantasma. g) Eritroplástido. h) Linfocito. i) Monocito. j) Mielocito. k) Metamielocito. l) Neutrófilo en banda. m) Neutrófilo maduro. n) Trombocitos inmaduros. o) Trombocitos inmaduros. Cada barra en las figuras representa 2µm.

kariolytic and eccentric nuclei (figure 2E and e). Ghost cells were also observed, corresponding to erythrocytes (figure 2F and f) and erythroplasts cellular remains and cytoplasmic residues (figure 2G and g).

LEUKOCYTE CELL LINE

Lymphocytes. The cells vary in form, but they predominantly are round-shaped, the nucleus occupies most of the cell and is surrounded by scarce cytoplasm

with basophilic aspect. Pseudopods were frequently observed (figure 2H and h). Lymphocytes measured between both groups of fish did not present significant differences ($P > 0.05$) (table 2).

Monocytes. Monocytes were observed as cells with irregular shape and big size. The nucleus was eccentric and surrounded by a slightly basophilic cytoplasm, where the vacuoles occasionally found (figure 2I and i). There was not significant difference ($P > 0.05$) between the monocytes measured in both group of fish (table 2).

Neutrophils. Myelocytes: this is the first maturation stage of the neutrophils, characterized by an eccentric round nucleus surrounded by a basophilic cytoplasm replete with fine granules of the same color (figure 2J and j).

Metamyelocytes: The second stage in the development of neutrophils, characterized by an eccentric reniform nucleus with a basophilic cytoplasm rich in fine granules of the same color (figure 2K and k).

Juvenile neutrophils (band): characterized by a nucleus in form of band with a basophilic cytoplasm (figure 2L and l). The immature neutrophils measured between both groups of fish did not present significant differences ($P > 0.05$) (table 2).

Mature neutrophils: characterized by a lobulated nucleus surrounded by basophilic cytoplasm containing great amount of fine granules of the same color. In *G. maculatus* the lobules of the mature neutrophil are around two or three (figure 2M and m). The mature neutrophils measured between both groups of fish did not present significant differences ($P > 0.05$) (table 2).

THROMBOCYTE CELL LINE

Immature thrombocytes. These cells have an elliptical form. The nucleus is elongated, occupying a great part of the cell and surrounded by a slightly basophilic cytoplasm (figure 2N and n). The immature thrombocytes between both groups of fish did not present significant differences on size ($P > 0.05$) (table 2).

Mature thrombocytes. These cells are generally gathered in cells groups. The nucleus is round and surrounded by scarce slightly basophilic cytoplasm (figure 2O and o). The mature thrombocytes between both groups of fish did not present significant differences on size ($P > 0.05$) (table 2).

DISCUSSION

The morphology of mature erythrocytes observed in *G. maculatus* is coincident with the morphologic descriptions reported for teleosts by different authors (Roberts 1981, Brown 1993, Stoskopf 1993, Takashima and Hibiya 1995, Tavares-Diaz 2006^{a,b}, Pavlidis *et al* 2007).

Mature erythrocytes in *G. maculatus* have smaller size than that described for Atlantic salmon, salmonids and teleosts in general (Lester and Budd 1979, Yasutake

and Wales 1983, Takashima and Hibiya 1995, Ballarin *et al* 2004, Pavlidis *et al* 2007). Furthermore, the relation length/width is low resulting in a more rounded shape. This could indicate that adults of *G. maculatus* have a less active behavior in comparison with other salmonids since the form of the erythrocytes is less efficient for the transport of oxygen, round-like shape cells have less contact surface in comparison with elliptical cells (Conroy 1972).

The erythroblasts in adult fish of *G. maculatus* represented 0.05% of the total erythrocyte cell line and they had a bigger size than the mature erythrocytes, contrary to what happens in mammals (Stoskopf 1993), but similar to what is reported by Lancioni *et al* (2005) for *Esox lucius*. Polychromatocytes were found in 0.48%, a value that is considered to be normal for teleosts by Ellis *et al* (1981), who also indicate that a fish considered healthy present around 1% of these cells. Ghost cells were detected in 2.20% of the total cells that were evaluated. These cellular remains indicate the destruction of erythrocytes which is a normal process that takes place at the end of the life cycle of such cells (Conroy 1972). The specialized literature does not make reference to the normal values for these erythrocyte remains but indicates that they are common part of the blood. The erythroplastids were found in 0.15% of the total analyzed cells. Again, there is not a reference value for healthy fish but it has been observed that there is a scarce presence of these cells in the periferic blood of healthy fish (Conroy 1972).

The lymphocytes, like the rest of the leucocytes found in *G. maculatus*, were morphologically similar to those described by previous authors (Conroy 1972, Ellis 1977, Roberts 1981, Yasutake and Wales 1983, Stoskopf 1993) in different species of fish and were present in most abundant amount than the rest of leucocytes ($77.20 \pm 0.98\%$). In adults of *G. maculatus* the monocytes, which are the blood cells with the biggest size ($10.59 \pm 2.34 \mu\text{m}$), were the less frequent leucocytes (8.6%). The concentration of monocytes in the blood tissue is depleted by bacterial diseases such as BKD and vibriosis (Lester and Budd 1979) and by the consumption of diets without vitamin E (Garcia *et al* 2007). Furthermore, the presence of monocytes is abundant in inflamed tissues (Suzuki and Iida 1992, Bruno and Poppe 1996).

In adults of *G. maculatus*, mature plus immature neutrophils were the second group of leucocytes in abundance, with 21.48% which is a value considered among the normal rank for teleosts (Olabeuena 2000). The morphology of these cells is similar to *Salmo salar* (Conroy 1972). These leukocytes of fine grain were mainly observed in their immature state. The scarce adult neutrophils presented a bilobulated nucleus in most of the cases. Stoskopf (1993) established that hyper-segmentations in the nucleus of these cells are a symptom of chronic and severe inflammations.

From the five groups of leukocytes, only three were present in adult fish of *G. maculatus*: leukocytes,

monocytes and neutrophils. The absence of thick grain leukocytes (basophiles and eosinophils) is coincident with other reports that indicate these cells are scarcely present in the peripheral blood, furthermore, their absence is usual in most teleosts fish (Olabeuena 2000, Tavares-Diaz 2006^a). This might be related to the fact that the granulocytes are located in other tissues, such as dermis, intestinal tissue, gills, natatory bladder, hematopoietic tissue, nasal epithelium, heart and inflamed tissue in general (Ellis *et al* 1981, Suzuki and Iida 1992, Olabeuena 2000, Valenzuela *et al* 2003). The granulocytes of thick grain belongs to an heterogeneous group of cells named mastocytes which plays a defensive role and are located in different tissues in the organism (Reite 1998).

There were no significant differences in the size and percentage between leucocytes of adult and larvae, so the leucocitary analysis that was done to adult fish of *G. maculatus* is similarly applicable to larvae.

The identification of thrombocytes is confusing, because the similarity of these cells in their mature stage with the lymphocytes (Tavares-Diaz 2006^a). However, mature thrombocytes are generally conforming cellular aggregates or coagulated groups; the nucleus stain with a more intense color than in lymphocytes, they do not have pseudopods and the cytoplasm is less basophilic in comparison with lymphocytes. There were not significant differences in the size and percentage between thrombocytes of adult and larvae, so the thrombocyte analysis for *G. maculatus* is applicable to adults and larvae.

Larvae of *G. maculatus* were characterized by the total absence of mature erythrocytes. This is also valid for previous stages of the development and could explain why Campos (1972) did not detect the state of the vitelline circulation in embryos of this species, and as opposed to *Brachygalaxias spp.*, where there was circulation of erythrocytes in the Cuvier's duct. In larvae of *G. maculatus* the elements of the erythrocyte line corresponded to polychromatocytes, characterized by the presence of a nucleus in state of cariolyisis. These cells could participate in the transport of oxygen in a less efficient way, because the maturation process of hemoglobin has not concluded. However, this possibility is discarded by Harding (1977) who mentions that the synthesis of hemoglobin takes place during the maturation of the erythrocyte cell and this is only mature when the erythrocyte reaches the adult stage. These cells are not capable to conclude the maturation process of hemoglobin and they reach a previous stage to the uptake of ferrous, when they are eliminated as product of the depigmentation strategy. It can be assumed that there is no presence of mature ferroproteins, which is in agreement with other investigations that describe the absence of iron in the peripheral blood of *G. maculatus* during the larvae state (Busse and Mösse 2006).

The blood cytology in larvae of *G. maculatus* is comparable to that described by Love (1970) for

Chaenocephalus aceratus or blackfin icefish, which also have a total absence of mature erythrocytes that transport oxygen in blood. This teleost is exposed to extremely low temperatures, a condition that generated, at one point of its evolution cycle, the production of antifreeze substances like serum nitrogen, calcium, cholesterol and glucose among others (Love 1970). The increasing viscosity in blood led to the total elimination of erythrocytes to obtain acceptable blood fluidity. In order to solve the problem of oxygen transport, this is restricted to the portion that is physically dissolved in the blood plasma (Malcom 1970, Busse and Campos 1996). Another fish with similar haematological characteristics is the larval stage of *Anguilla spp.* which lives in more warm temperatures (Haro and Krueger 1987). Therefore, this haematological phenomenon is not exclusive of fish living in extremely cold environments. This feature in *G. maculatus* might also be related to the morphology of the fish. The eel-like shape in larvae confer a higher contact surface (Busse and Campos 1996). Furthermore, the heart in larvae is 6 to 7 times bigger than a normal heart considering the body mass. This cardiac hypertrophy, which is even higher than that described for other species without hemoglobin (such as *Channichthyidae spp.*), drive to a boost of the blood caudal, improving the effectiveness of oxygen transport. The strategy for the oxygen transportation in larvae of *G. maculatus* is less efficient with the increment of water temperature which is normally between 7 and 15°C for this specie (Campos 1970).

It can be concluded that the blood cytology of common jollytail (*G. maculatus*), during the adult stage is similar to that observed in other teleosts. However, during the larval period this species does not exhibit mature erythrocytes in blood. In both states, neither the presence of eosinophils nor basophiles was detected in circulating blood. The results of the present report represent the first antecedent related to the blood haematology of *G. maculatus*. This basic information is highly valuable for the determination of blood parameters and it is also an important haematological tool for the pathologic diagnosis in this specie which is considered to have a high potential for Chilean aquaculture diversification.

SUMMARY

"Puye" (*Galaxias maculatus*) is a small freshwater fish species of great interest to Chilean aquaculture diversification, because of the high commercial value reached by its transparent larvae or "cristalino". This study presents the first data with regard to blood cytology in larvae and adults of this specie. Blood smears stained with May Grünwald-Giemsa were analysed through optical microscopy. The results show that in *G. maculatus* larvae the flowing blood has a transparent look and mature erythrocytes were not observed, as opposed to the adults of this species where the complete erythrocyte developmental line could be observed. In leucocytes, there was no presence of coarse grain cells such as basophils and eosinophils. In general, the morphology of the blood cells found in larvae and adults of *G. maculatus* have the same characteristic traits as described elsewhere in reports of other teleosts.

ACKNOWLEDGEMENTS

The authors would like to thank the Agro-aquaculture Nutritional Genomic Center (CGNA), belonging to the Regional Program of Scientific and Technological Development from CONICYT, and to the General Deanship of Research at the Catholic University of Temuco (DGI-UCT) for supporting this research work.

REFERENCES

- Ballarin L, M Dall'Oro, D Bertotto, A Libertini, A Francescon, A Barbaro. 2004. Haematological parameters in *Umbrina cirrosa* (Teleostei, Sciaenidae): a comparison between diploid and triploid specimens. *Comp Biochem Physiol A* 138, 45-51.
- Barile J, A Bórquez, P Dantagnan, A Mardones, J Quevedo, I Salgado, I Valdebenito, R Vega. 2003. Antecedentes para el cultivo del puye *Galaxias maculatus* (Pices: Galaxiidae). Gráfica Sur Ltda., Temuco, Chile.
- Berra T, L Crowley, W Ivantsoff, P Fuerst. 1996. *Galaxias maculatus*: an explanation of its biogeography. *Mar Freshwater Res* 47, 845-849.
- Bórquez A, P Dantagnan, N Valdebenito, J Bariles, R Vega. 1996. Crecimiento y sobrevivencia larval de *Galaxias maculatus* con diferentes densidades de cultivo. En: Silva A, Merino G (eds). *IX Congreso Latinoamericano de Acuicultura y 2º Simposio Avances y Perspectivas de Acuicultura en Chile*. Universidad Católica del Norte, Coquimbo, Chile, Pp 255-258.
- Brown L. 1993. *Acuicultura para veterinarios*. Abbott Laboratotes, North Chicago, USA.
- Bruno D, T Poppe. 1996. *A Colour Atlas of Salmonid Diseases*. Academic Press, London, UK.
- Busse K. 1993. On a green pigment in the blood-serum of subadult lacustrine *Galaxias* (Pisces:Galaxiidae). *Bonn Zool Beitr* 44, 125-131.
- Busse K, H Campos. 1996. Galaxiiden- Jungfische ohne Hämoglobin. *Tier und Museum, Bonn*, 5, 48-54.
- Busse K, T Möser. 2006. Zur fortpflanzungsbiologie von *Galaxias maculatus* (Osmeriformes:Galaxiidae) zuchtversuche und erprohung der laichwanderungen im süßwasser-seewasser-aquarium. In: Greven H, Riehl R (eds). *Biologie der Aquarienfische*. Tetra Verlag, Berlin, Germany, Pp 19-25.
- Campos H. 1970. *G. maculatus* (Jenyns, 1842) en Chile, con especial referencia a su reproducción. *Bol Mus Nac Hist Nat Chile* 31, 5-20.
- Campos H. 1972. The species problem in freshwater fishes and the taxonomy of diadromous and lacustrine populations of *Galaxias maculatus* (Jenyns). *J Roy So* 3, 325-367.
- Conroy D. 1972. Studies on the hematology of the Atlantic Salmon (*Salmo salar*). *Zool Soc Lon* 30, 101-127.
- Dantagnan P, A Borquez, J Bariles, I Valdebenito, R Vega. 1995. Effects of different diets on the survival and growth of puye (*Galaxias maculatus*). *EAS Special Publication* 24, 435-437.
- Dantagnan P, A Bórquez, J Quevedo, I Valdebenito. 2002. Cultivo larvario del puye (*Galaxias maculatus*), en un sistema cerrado de recirculación. *Investigación Tecnológica* 13, 15-21.
- Dantagnan P, MS Izquierdo, A Bórquez, A Espina, I Salgado. 2004. Culturing of *Galaxias maculatus* (Galaxiidae:osmeriform) at different salinities: effect of increasing levels of total PUFA, under constant relationships of n-3/n-6PUFA. *EAS Special Publication* 34, 261-262.
- Dantagnan P, MS Izquierdo, A Bórquez, N Valdebenito, E Serrano. 2005. Change of lipid and fatty acid composition during development of *Galaxias maculatus* (Osmeriforme:Galaxiidae) eggs and larvae. *EAS Special Publication* 36, 111-114.
- Dantagnan P, A Bórquez, I Valdebenito, I Salgado, E Serrano, MS Izquierdo. 2007. Lipid and fatty acid composition along embryo and larval development of puye (*Galaxias maculatus* Jenyns, 1842) obtained from estuarine, fresh water and cultured populations. *J Fish Biol* 70, 770-781.
- Ellis AE. 1977. The leucocytes of fish: A review. *J Fish Biol* 11, 453-491.
- Ellis A, R Robert, P Tyler. 1981. Anatomía y fisiología de los teleósteos. En: Robert R (ed). *Patología de los peces*. Mundi-Prensa, Madrid, España, Pp 15-61.
- García F, F Pilarski, E Makoto, F Ruas de Moraes, M Laterca. 2007. Hematology of *Piaractus mesopotamicus* fed diets supplemented with vitamins C and E, challenged by *Aeromonas hydrophila*. *Aquaculture* 271, 39-46.
- Ham D. 1988. *Histología*. Editorial Harla, México.
- Harding J. 1977. Maturation of circulation red blood cells in young Baltic salmon (*Salmo salar*). *Acta Physiol Scand* 102, 290-300.
- Haro A, W Krueger. 1988. Pigmentation, size, and migration of elvers (*Anguilla rostrata* (Lesueur)) in a coastal Rhode Island stream. *Can J Zool* 66, 2528-2533.
- Lancioni H, L Lucentini, F Panara. 2005. Ontogenetic changes of circulating erythroid cells and haemoglobin components in *Esox lucius*. *J Fish Biol* 66, 1576-1588.
- Lester R, J Budd. 1979. Some changes in the blood cells of diseased Coho salmon. *Can J Zool* 57, 1458-1464.
- Love R. 1970. *The chemical biology of fishes. With a key to the chemical literature*. Academic Press, New York, USA.
- McDowall RM. 1970. The galaxiid fishes of New Zealand. *Bull Comp Zool* 139, 341-431.
- McDowall RM. 1971. The galaxiid fishes of South America. *Zool J Linn Soc* 50, 33-73.
- McDowall RM. 1981. The galaxiid fishes of Australia. *Rec Australian Mus* 33, 443-695.
- McDowall RM. 1984. Southern Hemisphere freshwater salmoniforms: Development and relationships. In: Moser HG, Richards WJ, Cohen DM, Fahay MP, Kendall AW, Richardson SL (eds). *Ontogeny and systematics of fishes*. American Society of Ichthyologists and Herpetologists, Special Publication 1, 150-153.
- McDowall RM. 1988. *Diadromy in fishes: migrations between freshwater and marine environments*. Timber Press, Portland, Oregon, USA.
- Olabeuena E. 2000. Sistema inmune de peces. *Gayana* 64, 205-215.
- Oppenheim I. 1973. *Manual para técnicos de laboratorio*. Editorial Panamericana, Buenos Aires, Argentina.
- Pavlidis M, WC Futter, P Khatarios, P Divanach. 2007. Blood cell profile of six Mediterranean mariculture fish species. *J Appl Ichthyol* 23, 70-73.
- Reite O. 1998. Mast cells/granule cells of teleostean fish: a review focusing on staining properties and functional responses. *Fish Shellfish Immun* 8, 489-513.
- Roberts R. 1981. Fisiopatología sistémica de teleósteos. En: Roberts R (ed). *Patología de los peces*. Mundi-Prensa, Madrid, España, Pp 103-117.
- Stoskopf M. 1993. *Fish medicine*. WB Saunders, Philadelphia, USA.
- Suzuki Y, T Iida. 1992. Fish granulocytes in the process of inflammation. *Ann Rev Fish Diseas* 2, 149-160.
- Takashima F, T Hibiya. 1995. *An Atlas of Fish Histology. Normal and Pathological Features*. Kodansha, Tokyo, Japan.
- Tavares-Dias M. 2006^a. A morphological and cytochemical study of erythrocytes, thrombocytes and leukocytes in four freshwater teleost. *J Fish Biol* 68, 1822-1833.
- Tavares-Dias M. 2006^b. Cytochemical method for staining fish basophils. *J Fish Biol* 69, 312-317.
- Valenzuela A, C Oyarzún, V Silva. 2003. Células sanguíneas de *Schroederichthys chilensis* (Guichenot 1848) (Elasmobranchii, Scyliorhinidae) la serie blanca. *Gayana* 67, 130-136.
- Waters J, C Burrige. 1999. Extreme intraspecific mitochondrial DNA sequence divergent in *Galaxias maculatus* (Osteichthyes: Galaxiidae), one of the world's most widespread freshwater fish. *Mol Phylogenet Evol* 11, 1-12.
- Yasutake W, J Wales. 1983. *Microscopic anatomy of salmonids: an atlas*. US Fish Wildlife Service. Resource Publication, Washington DC, USA.